

Acyclovir Induced Nephrotoxicity

Pedro Arriaga¹ and Jorge Luis Hidalgo²

Abstract

Acute kidney injury is a well recognized side effect of some medications, and has been well described as an unfortunate complication with the use of acyclovir. The most common presentation of this type of injury is an acute decrease in renal function that develops within 24-48 hours with rapid increase in the level of serum creatinine. The most common mechanism of this type of lesion seems to be that of a crystal nephropathy and although it is a very well known side effect, has been poorly noticed.⁽⁸⁾ This case clearly describes the clinical manifestations of this type of nephrotoxicity.

Keywords: acute kidney failure, acyclovir nephrotoxicity, crystal nephropathy.

Case History

The patient is a 43 year old male evaluated in the outpatient clinic 72 hours before admission, and treated with acyclovir 800 mgs orally five times daily, amitriptyline HCl 75 mg and codeine 30 mg every 8 hours, after being diagnosed with Herpes zoster, which affected him for the previous 2 days. At the time of the first evaluation, the patient presented with history of malaise, fever, and vesicular type rash to the left side of his chest that was accompanied by severe burning pain. The following day, the patient returned to the Emergency Room complaining of severe pain to his torso, and was admitted for observation. During this time, he received 3 doses of acyclovir 600 mg IV, one dose of diclofenac 75 mgs IV and was then discharged. Forty eight hours later, the patient returned to the Emergency room complaining of facial and pedal edema plus urinary retention.

Physical Exam

The patient was afebrile; showed normal fundoscopy and wet oropharynx with no lesions. There were no masses or adenopathies on the neck. The face showed mild to moderate edema. The chest was symmetrical; there was no use of accessory muscles. The heart had good rhythm, no murmurs were heard. The lungs were clear with good air entrance. The abdomen was soft and depressible with no visceromegaly. The extremities presented bilateral pedal edema. Multiple crops of red-colored vesicles were observed on the skin of the left side of the chest consistent with T4 and T5 dermatomes.

Clinical laboratory findings

Hemoglobin = 15 gr/dL, white blood cell count= 8000 cells/mm², polymorphonuclears = 72.4 %, lymphocytes = 18%, monocytes = 9.6%. BUN = 68 mg/dL, serum creatinine = 6.4 mg/dL, K = 4.18 mEq/L, Na = 140 mEq/L. HIV test was negative.

Urinalysis: pH: 6.6, protein: negative, SG: 1015, white blood cell count: 7-8 hpf, bacteria: negative, granular casts (2+)

1. Corresponding author: Pedro Arriaga MD
Head of the Internal Medicine Department
email: prarr@yahoo.com

2. MD, Head of Critical Care
Karl Heusner Memorial Hospital, Princess Margaret Drive,
Belize City, Belize

Clinical Progression

The patient was admitted to the Internal Medicine Ward with a possible diagnosis of crystal-induced nephropathy. Strict control of intake and output was ordered, and furosemide treatment was used to maintain urine output at least 75 cc/hour.

After reaching the maximum peak, serum creatinine level on the second day of admission (7.3 mg/dL) began to return to baseline over the next 5 days (see table 1). The total amount of acyclovir given was 1200 mg IV and a total of 4 grams had been given orally by the time the kidney injury was detected. This patient had no other risk factors to explain any renal injury and remained fairly asymptomatic during the entire length of his admission in the hospital.

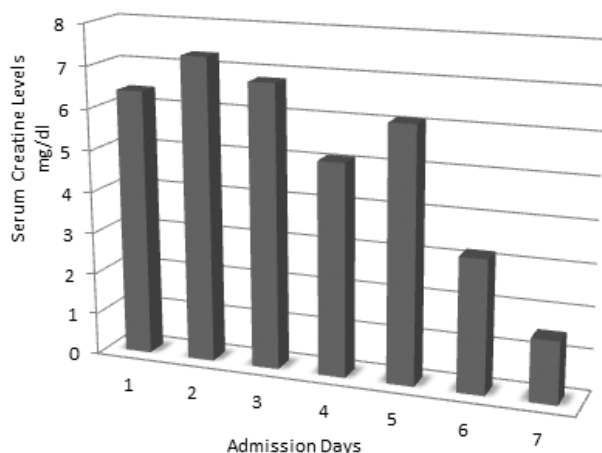


Table 1. Progression of serum creatinine levels during the days of admission to the hospital

Discussion

The incidence of acute renal failure (ARF) is difficult to establish due to the amount of existing ARF definitions. But, in general, ARF represents 1% of hospital admissions and occurs in 2-5% of in-hospital patients. ARF is present in 1-25% of patients admitted to ICU. Drug induced renal failure occurs in 18-27% of patients with ARF, and 20% of patient admissions with ARF has been related to drugs (especially NSAIDs) (4). This paper describes a patient with no previous history and no underlying co-morbidities developing an acute renal injury secondary to an obstructive uropathy after receiving acyclovir

therapy. Acyclovir-induced renal failure has been reported since its introduction in the late 1970s. Renal metabolism accounts for 75-80% of acyclovir clearance (unchanged drug accounts for 60-90% of its elimination) (2,3). Renal clearance of this drug is approximately three times that of creatinine, suggesting rapid elimination via glomerular filtration and tubular secretion and producing high concentration of the drug in the tubular lumen. Acyclovir is relatively insoluble in urine especially in the distal tubular lumen (urine flow here is slow), so this drug could produce intratubular precipitation of crystals causing an obstructive nephropathy. (2,3) The urine test of this patient was reported devoid of crystals, but, without polarizing light microscopy, they can be missed. The oral form of acyclovir has poor bioavailability and has been related to renal injury only when the patient is severely dehydrated, compared to the IV presentation that reaches high blood concentrations, explaining why renal injury is most common with IV administration. Also, there have been reports of renal injury in patients using valacyclovir formula and famciclovir(2,3,4,6)

Factors that increase probability of this type of injury are: pre-existing renal disease, dehydration, simultaneous use of other nephrotoxic agents, use of an intravenous bolus, and dosage > 1500mg/m² per day. Most of these cases are self-limited and reversible once the drug is discontinued and the patient receives good intake of IV fluids (3L/m²/d). If renal failure is severe, hemodialysis should be considered.(3,7)

Conclusion

The importance of monitoring renal function in patients using acyclovir, especially the IV form, must be emphasized. Clinical evaluation and previous medical history are critical parts of decision making when selecting medications for any patient and it is a priority for clinicians to be familiar with the potential side effects of medications.

References

1. Delluc A; Mocquard Y; Latour P; Goas JY. Encephalopathy and acute renal failure during acy clovir treatment. Rev Neurol (Paris), 2004; 160: 704-6

2. Eman R Al-Matter, Mona H Bourahma, Kadankandy C Aboobacker. Acyclovir Induced Reversible Renal Failure in an Immunocompromised Child with Extensive Cutaneous Herpes Zoster. Kuwait Medical Journal 2004, 36: 47-48
3. Fleischer R, Johnson M. Acyclovir nephrotoxicity: A case report highlighting the importance of prevention, detection and treatment of acyclovir induced nephropathy. Case Reports in Medicine Volume 2010, Article ID 602783, 3 pages
4. Howell HR, Brundige ML, Langworthy L. Drug induced renal failure. US Pharm. 2007;32:45-50
5. Johnson GL, LimonL, Trikha G, Wall H. . Acute renal failure and neurotoxicity following oral acyclovir. Ann of Pharmacother.1994;28:460-3
6. Perazella Ma. Drug induced renal failure: Update on new medications and unique mechanisms of nephrotoxicity. Am J Med Sci.2003;325:349-362
7. Sawyer MH, Webb DE, Balow JE, Strauss SE. Acyclovir-induced renal failure. Clinical course and histology Am J Med 1988;84:1067-71
8. Vela F, Sanchez AR, Cabanete F, Vicente A, Benavides R. Acyclovir induced renal failure: An underestimated secondary effect. An Pediatr (Barc). 2008;69:171-4

When HPV genital
warts appear...

Imik[®] crema
Imiquimod 5 %

