

A 56-year-old male patient
 referred to us with complaints of abdominal pain and weight loss.
 Panabdominal ultrasound and abdominal CT were performed.
 Ultrasound and tomographic images are presented.



• *Please respond ...*

Julio Manuel Díaz Riverol¹

Citation:

Díaz Riverol JM. Radiographic quiz
 BJM 2021; 10(2):8-9

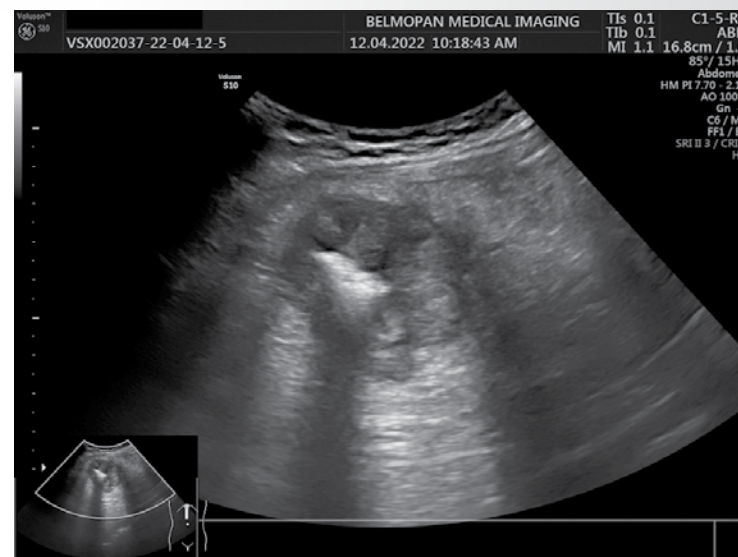


Image 1

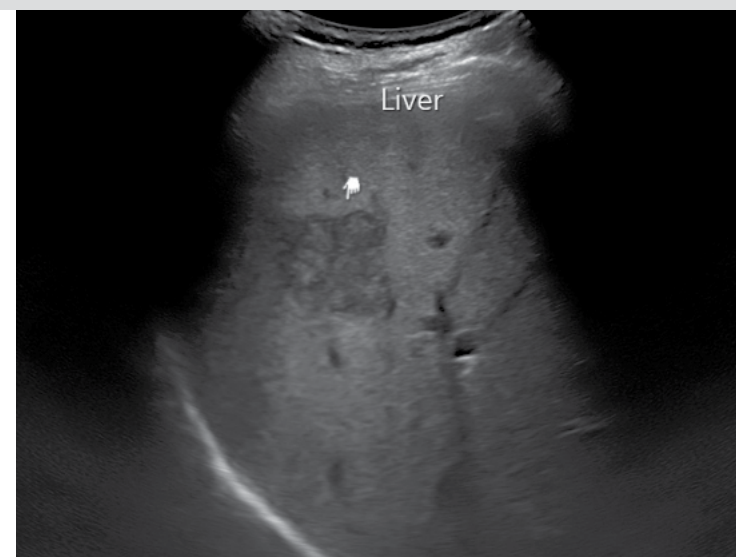


Image 2

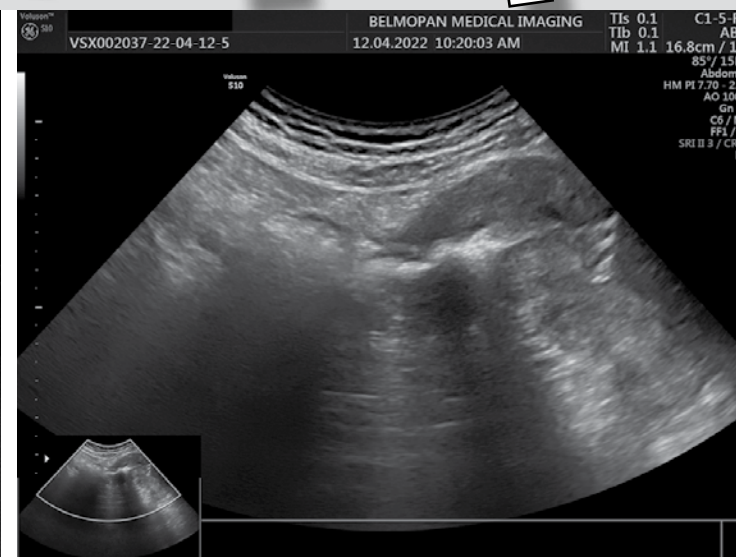


Image 3

Regarding to ultrasound images which organs are affected

- ☐ Liver and kidney
- ☐ Stomach and kidney
- ☐ Liver and colon
- ☐ Stomach and liver

The ultrasound findings are compatible with:

- ☐ Colon cancer and liver metastasis
- ☐ Renal mass and liver metastasis
- ☐ Stomach mass and liver cyst
- ☐ Stomach mass and kidney malformation

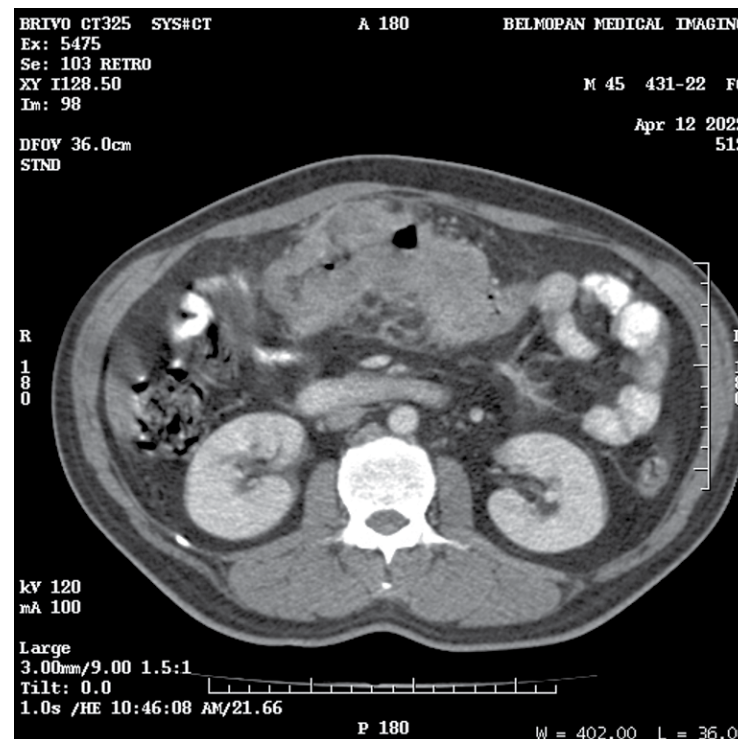


Image 4

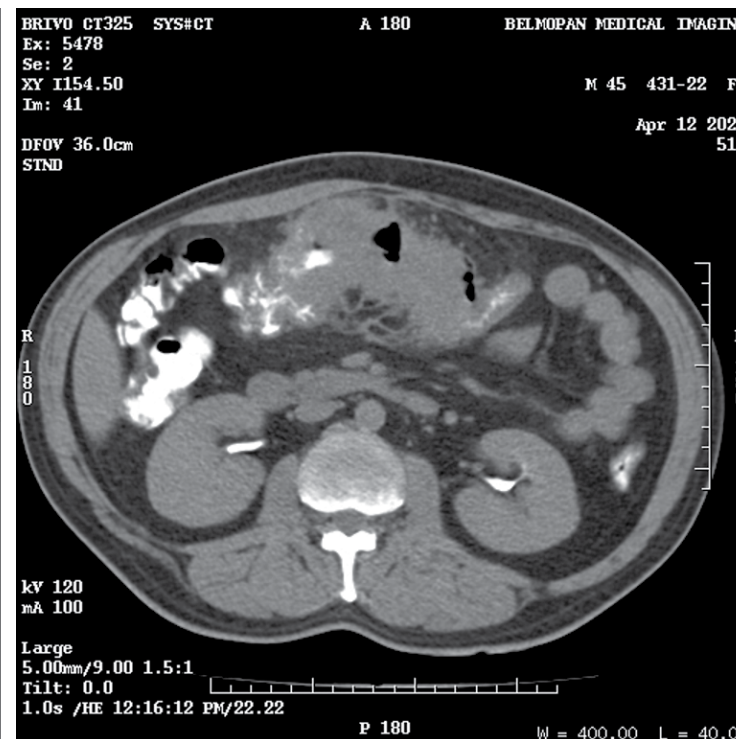


Image 5

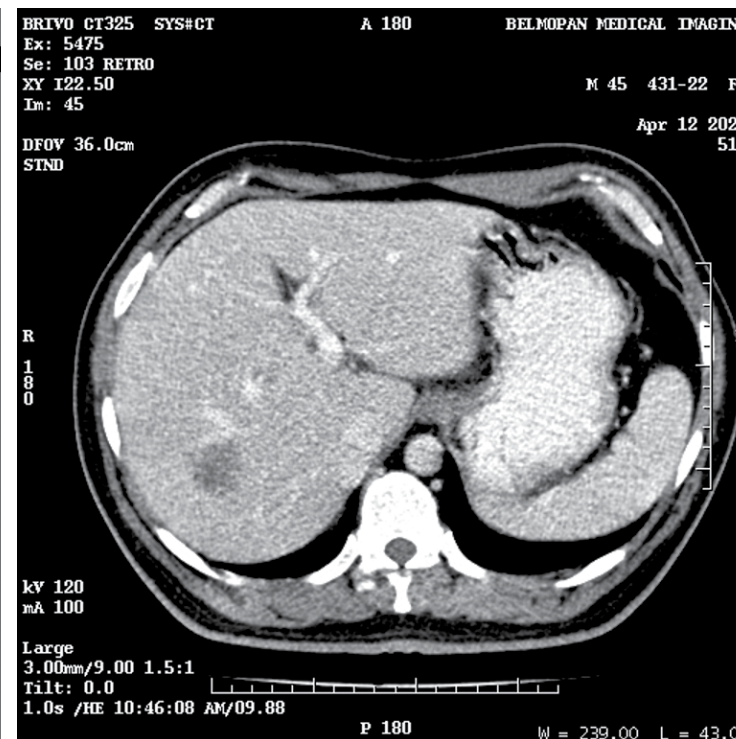


Image 6

Regarding to tomographic images which is the best description for the findings showed

- ☐ Soft tissue density that narrow the bowel lumen
- ☐ Hyperdense mass with focal calcifications
- ☐ Multiseptated mass
- ☐ Soft tissue density that narrow the bowel lumen and hypodense hepatic mass

What is your diagnostic?

- ☐ Gastric carcinoma and hepatic cyst
- ☐ Hepatocellular carcinoma and abdominal abscess
- ☐ Colon cancer and hepatic metastasis
- ☐ Pancreatic mass and hepatic metastasis