

Perinatal hypophosphatasia

Wendy Ríos Navarrete¹

Summary[1]

Perinatal hypophosphatasia is a rare and severe disease associated with a reduction in tissue non-specific alkaline phosphatase synthesis due to a deletion or a mutation of its gene located on chromosome 1. These patients present severe bone demineralization, low levels of alkaline phosphatase and increase of urinary and serum pyrophosphate and phosphoethanolamine. The condition can be lethal in utero or after birth due to inadequate bone support of the chest and skull, although patients with milder phenotypes can survive until adulthood.

A case of a female patient is presented. She was 21 days old, of Mennonite origin, with a history of generalized tonic-clonic movements and irritability from the second day of life. She does not show improvement with phenobarbital treatment; therefore, x rays and laboratory tests are indicated. Perinatal hypophosphatasia is confirmed. The patient is stabilized and included in a group of experimental enzymatic treatment in Canada.

Key words

perinatal hypophosphatasia, tonic-clonic movements, radiological findings, treatment

INTRODUCTION

Perinatal hypophosphatasia is a rare and severe disease, associated to reduction in the synthesis of tissue non-specific alkaline phosphatase (TNSALP) due to a deletion or a mutation of its gene located on chromosome 1. The variety of the mutations that occur in the alleles of this chromosome can cause great variability in the clinical expression of the disease and a large number of compound heterozygous genotypes. At least two mutations have been detected that occur in specific populations: one is present in Japanese patients and the other in Canadian Mennonites. These are lethal when present in both alleles.

The prevalence of severe hypophosphatasia at birth was estimated in 1/100,000, based on registries of pediatric hospitals in the United States. The incidence of milder forms has not been estimated, but it is assumed to be much higher, due to the number of patients with dominant forms that carry the same mutations found in cases of recessive hypophosphatasia.

Description and clinical forms

Clinical expression covers a wide range, from fetal death without bone mineralization to pathological fractures appearing at adulthood. Depending on the age at diagnosis, five forms are generally recognized:

1. Neonatal: the most lethal form, since the newborn shows noticeable lack of bone mineralization, causing closure of the

fontanelles, malformation of the limbs and limitation of chest expansion. They have respiratory complications, seizures and remarkable shortening of the bones of the extremities.

2. Infantile: babies can be apparently normal at birth, but symptoms appear in the first 6 months of life. They can show growth retardation, alteration of the long bones, alteration of motor development, hypercalcemia, hypercalciuria, anorexia and vomiting, hypotonicity, dehydration and predisposition to pneumonia.

3. Childhood: appears before the age of 5; it is characterized by hypoplasia or aplasia of the dental cement, low size, dolichocephalic skull with frontal bulging and skeletal alterations secondary to rickets, frequent fractures and bone pain. The signs recur during adulthood.

4. Adult: infrequent form, characterized by bone demineralization with osteomalacia that predisposes to recurrent stress fractures (metatarsals, proximal femur).

5. Odontohypophosphatasia: is present when there are dental alterations exclusively.

It is necessary to point out that some of these forms overlap and share clinical symptoms.

Radiological tests

A complete study of the skeleton should be carried out in hypophosphatasia suspect patients. By simple radiology, osteopenia and chondrocalcinosis and/or pathological fractures can be observed; however, there is no pathognomonic finding. When bone biopsy is performed, histology is compatible with osteomalacia.

¹ MD, Pediatrician, The Pediatric Center, 115 Freetown & St. Thomas St. Belize, Belize. E-mail: alendyro@hotmail.com

Almost total absence of bone mineralization is frequent in fatal cases. Fractures and rickets commonly appear. Absence of skeleton development is also observed in survivors, but it is generally less severe. Premature craniosynostosis can occur. Rachitic deformations characterize the disease in children. Upon radiological examination of metaphyses, projections of epiphyses towards them can be observed, finding not present in other types of rickets.

Pseudofractures are a distinctive characteristic of hypophosphatasia in adults, frequently of the proximal femur zone. There is also increasing incidence of non-healing fractures, especially of the metatarsal bones.

Renal ultrasound can show nephrocalcinosis,

Differential diagnosis with osteogenesis imperfecta, rickets and achondrogenesis should be done.

Management and Treatment

At present hypophosphatasia has no cure, therefore specific medical treatments are not available. There are symptomatic treatments, used jointly with orthopedic management, to palliate the symptoms.

Cranial hypertension caused by craniosynostosis may require surgery to avoid brain damage in newborns.

Fractures and bone deformities are complicated by the lack of mineralization and skeleton growth impairment in these patients and their consolidation can be prolonged. It is necessary to carry out periodical check ups with a dentist to prevent dental problems.

Non-steroid anti-inflammatory medications can be administered to eliminate pain and inflammation.

Vitamin D and supplements, traditionally used for rickets, are not indicated in these patients.

Bone marrow transplantation treatments have been experimented, which showed some result and intravenous infusions of plasma enriched in soluble alkaline phosphatase for enzyme replacement, which did not give any result.

At present, the most promising clinical trial is being carried out in several countries by replacement therapy using the recombinant TNSALP ENB-0040.

CASE PRESENTATION AND DISCUSSION

Twenty-one day old female patient of Mennonite origin presenting generalized tonic-clonic movements and irritability from the second day of life, for which phenobarbital treatment was initiated; but is referred since there was no improvement.

The clinical record reports birth by cesarean section. The girl weighed 8 lbs with 4'9" APGAR and is fed breast milk. In the Emergency Unit, the patient presented respiratory difficulty and generalized tonic-clonic convulsions. She has no fever and is cyanotic. Vital signs show a temperature of 99.0 F, heart frequency: 188/min, respiratory frequency: 67/min, saturation: 69%. Orotracheal intubation is done and mechanical ventilation and sedation started, but movements of the lower extremities are still observed. The patient is taken to the intensive care unit, where antibiotic therapy is begun, intravenous liquids and anticonvulsive medications are administered and laboratory studies are requested.

Laboratory results

Hematology: hemoglobin 13.4 g/dL, leukocyte count 17.8%, platelets 541,000/mm³, neutrophils 76% and lymphocytes 24%.

BUN (blood urea nitrogen) 15 mg/dL, calcium 9.9, creatinine 0.7 mg/dL, potassium 5.77 mmol/L, sodium 142.9 mmol/L. Cerebrospinal liquid: protein 74.8 mg/dL, glucose 127mg/dL, leukocyte count 0, erythrocyte count 0, gram negative, alkaline phosphatase 10 IU/L.

Radiological results[2]

Radiologically, demineralization and changes compatible with rickets at the femur and rib level bone metaphyses were observed.

With the TNSALP and radiologic results, neonatal hypophosphatasia was diagnosed. It consists of a deficiency of alkaline phosphatase activity, having an estimated incidence of 1/100,000. With this information intramuscular 10 mg pyridoxine is indicated and immediately convulsions cease. In the intensive care unit, treatment with antibiotics, anticonvulsants and pyridoxine was initiated. After 48 hours, mechanical ventilation is removed; the patient ceases convulsing and the oral route is initiated.

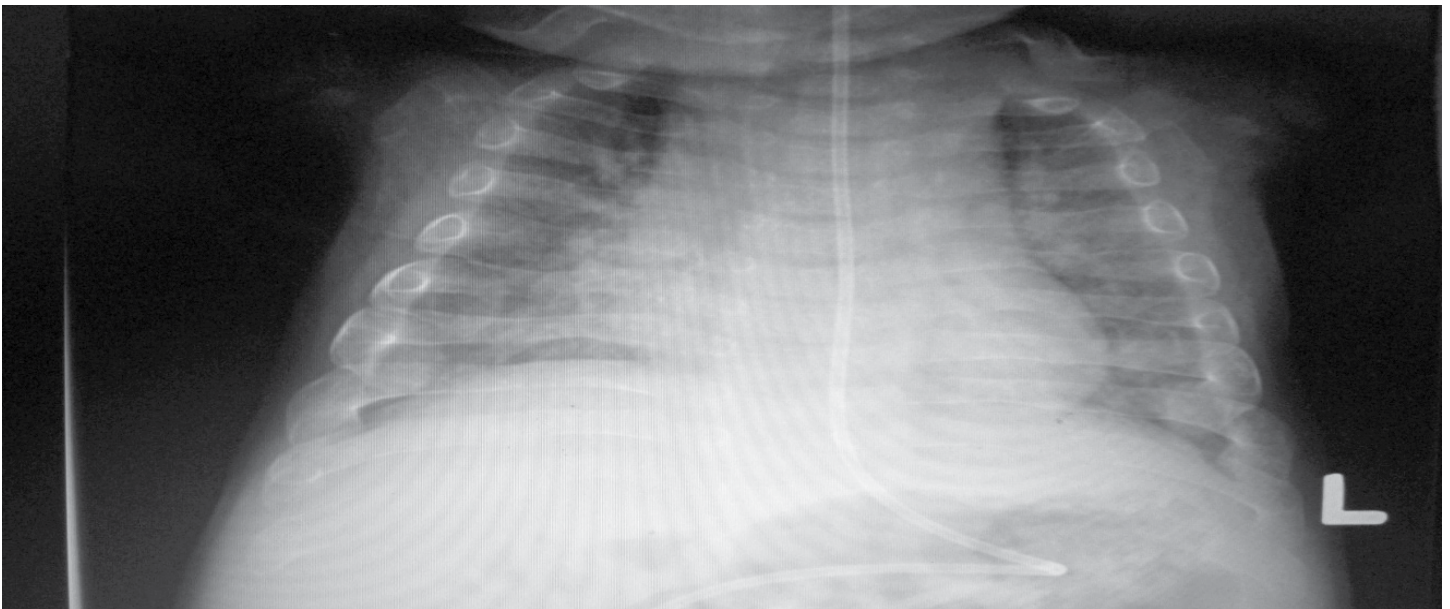
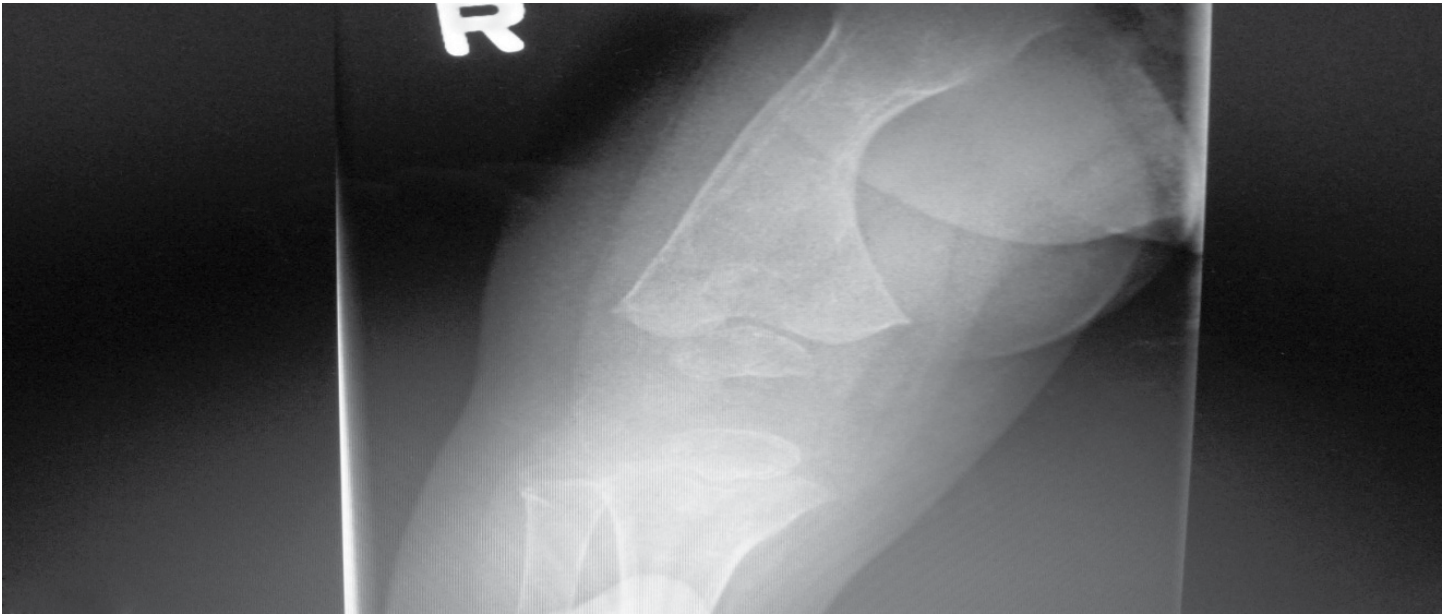
Steps were taken so that she may be included in an experimental treatment carried out in Canada, The United States and China. Contact is established with the Children's Hospital of the Winnipeg Health Sciences Centre, Winnipeg, Canada, where the experimental treatment for this disease is given. The patient fulfills all criteria for inclusion in the trial and is accepted. The parents agree with the treatment, after explaining it is experimental, but it is the girl's only opportunity of surviving.

In July 2010 the patient arrived at said hospital and was enrolled in the treatment with ENB-0040 (20/mg/day, subcutaneously) for perinatal/infantile hypophosphatasia, which causes severe bone disease, short extremities, rickets and bone demineralization and remarkable hypercalcemia, originating severe acute problems (nephrocalcinosis, hypertension and feeding difficulty and therefore malnutrition). At this hospital she is treated by endocrinologists, neurologists, nutritionists, gastroenterologists and intensivists.

Now, the patient is one and a half year old and still under treatment. She is taken to Canada for one week every six weeks and an important progress has been noted, both physically and in mental development. The patient is fed a calcium-restricted formula, currently 900 mL in 24 hours by oro-tracheal tube with a continuous infusion pump. Semisolids were introduced in the diet, which have been well tolerated. She can sit without help and the fine motor area shows progress. She continues under treatment with pyridoxine, esomeprazol PO, 400 IU of vitamin D/day and hydrochlorothiazide 3 mg bid.

CONCLUSION

The lesson from this case is that there are many different causes for neonatal seizures, thus it is always important to investigate and have the collaboration of other specialties. In this case the radiologist was a great help in diagnosing the disease, which is not common in our environment, since it



is very infrequent and the survival of these patients is quite short.

ACKNOWLEDGEMENTS

I thank the Children's Hospital in Winnipeg, Canada, for providing help and collaboration in this interesting case and the parents of the patient for their cooperation, without which, it would not have been possible to subject the girl to an experimental treatment that in her case has been almost curative.

REFERENCES

1. Kellsey DC. Hypophosphatasia and congenital bowing of the long bones. *JAMA* 1962, 179:187-190
2. Whyte MP. "Hypophosphatasia". In Scriver CR, Beaudet AL, Sly WS, Valle D, Vogelstein B. *The metabolic & molecular bases of inherited disease*. New York: McGraw-Hill. 2001. 5313-29.
3. Whyte MP, Greenberg CR, Salman NJ, Bober MB, McAlister WH, Wenkert D, et al. Enzyme-Replacement Therapy in Life-Threatening Hypophosphatasia *N Engl J Med* 2012;366:904-13.